

# Necrotizing Fasciitis of the Thigh... or is the Source More High?

Jennifer Wolff, MD

Department of Emergency Medicine, Department of Internal Medicine

## INTRODUCTION

- There are uncommon circumstances where the source of necrotizing fasciitis lies beyond the boundaries of the superficial tissues.
- We describe a case of right thigh necrotizing fasciitis that originated from an abscess surrounding a perforated staghorn calculus of the right kidney.
- This is the first case of necrotizing fasciitis originating from an infected, perforated calculus described in the Emergency Medicine literature.

## CASE PRESENTATION

A 47-year-old bed-bound woman with rheumatoid arthritis on prednisone, transverse myelitis, and kidney stones presented with several days of malaise, generalized weakness, confusion and acute on chronic right hip pain. There is no known injury, sick contact, or dysuria.

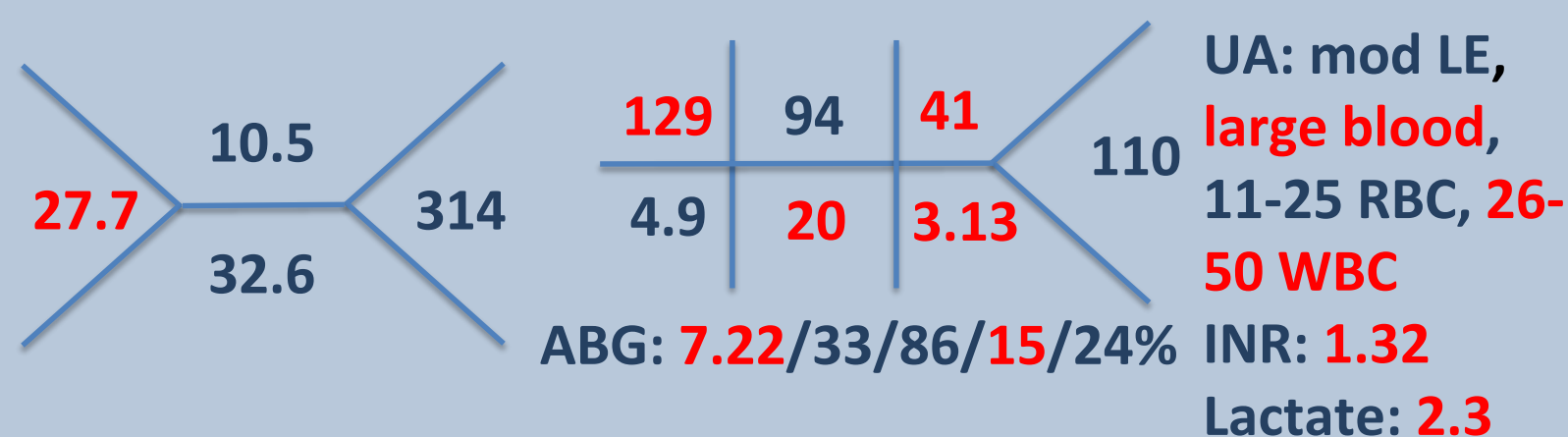
### Physical Exam:

Vitals: HR 100, BP 85/64, T 38.2C, RR 18, O2 95%

General: **Ill appearing**

Abd: Obese, soft, non-tender and non-distended, mild right flank tenderness, no erythema

Extremities: Right lower extremity with **erythema and tenderness** in proximal anterior and medial thigh, pain with passive movement, **+ crepitus**



## IMAGES

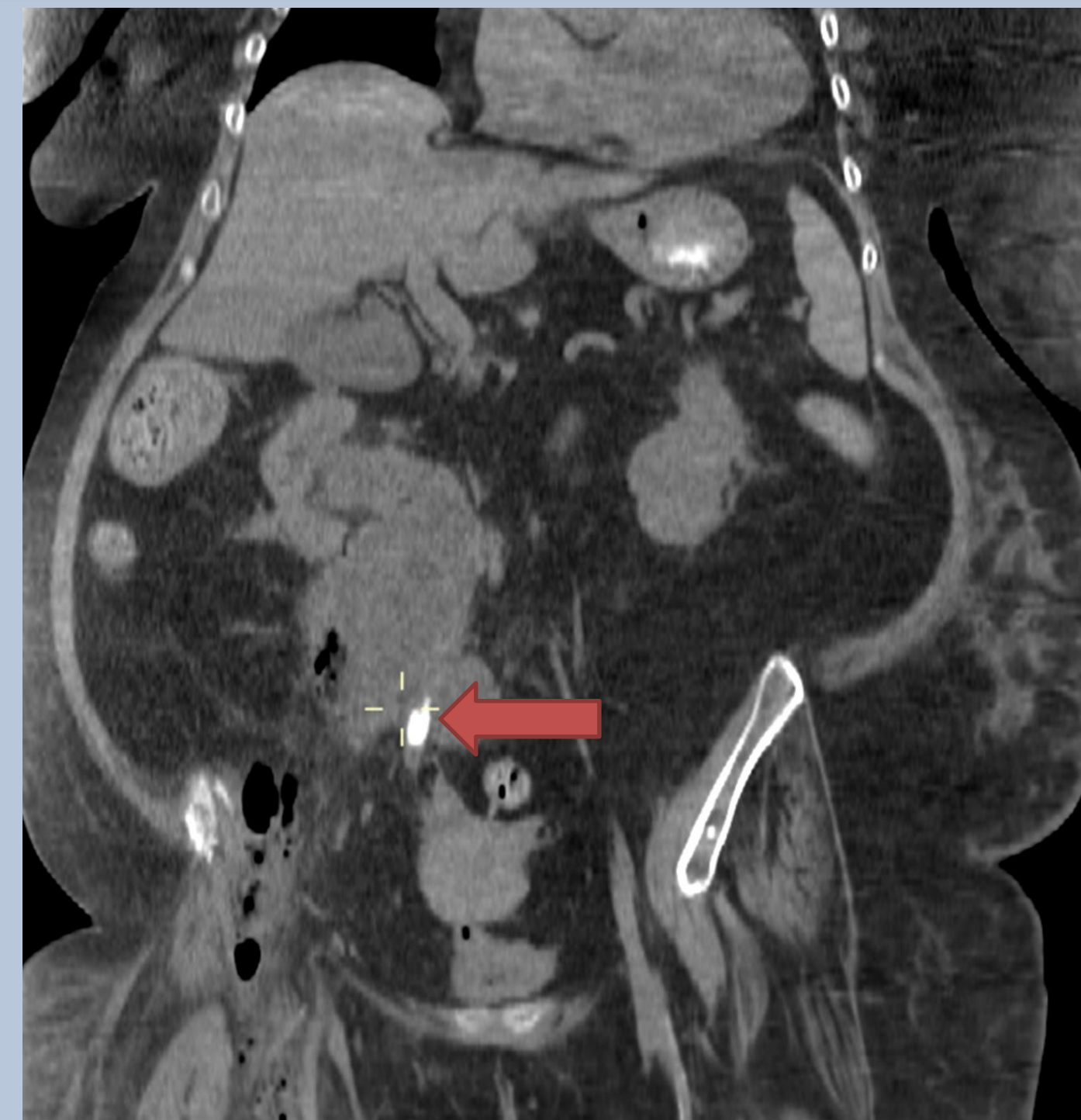

Image 1: CT without contrast demonstrating perforated kidney stone (arrow) with surrounding abscess and air.

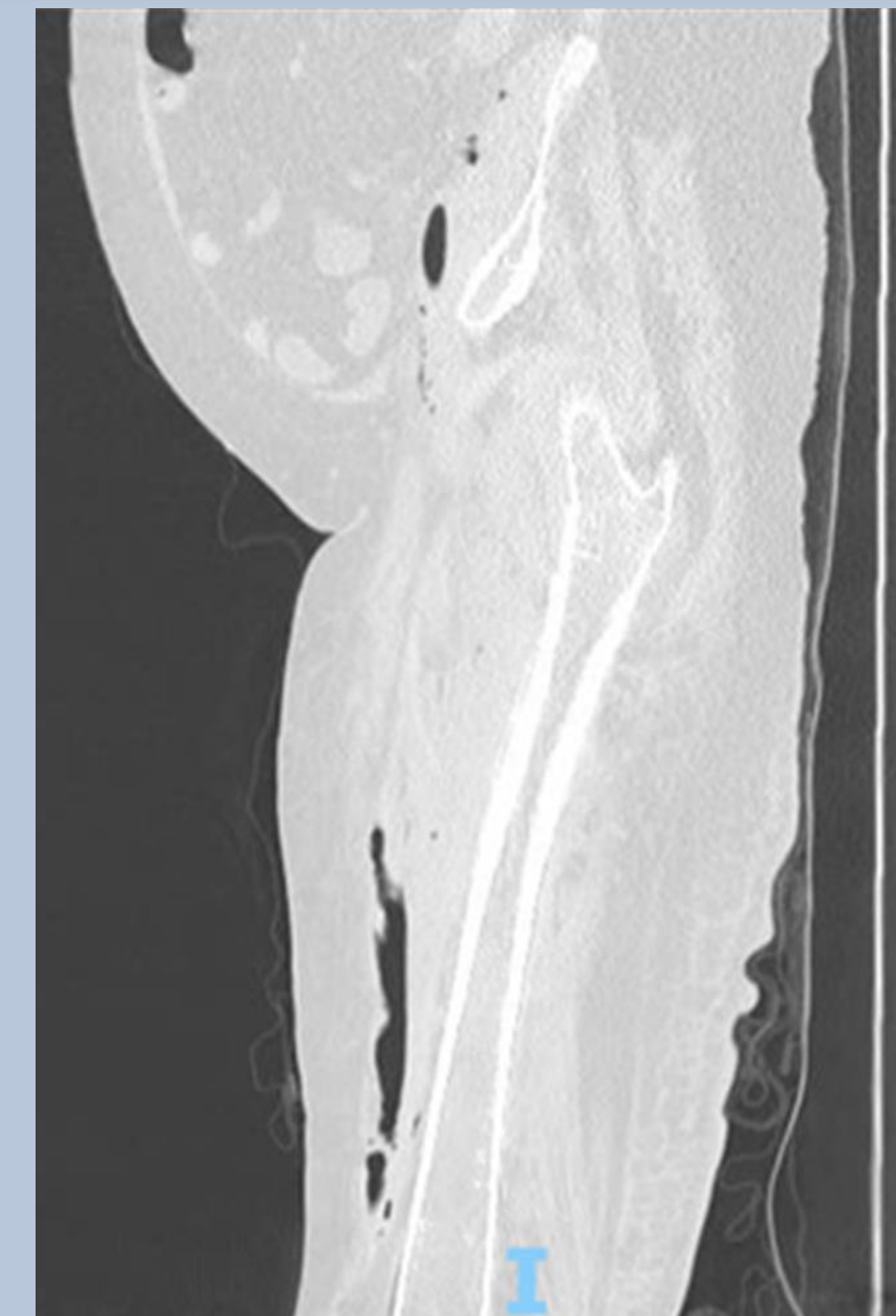


Image 2: CT demonstrating gas tracking from the retroperitoneum to the right leg.

## MANAGEMENT



Vancomycin, pip/tazo, clindamycin administered in ED



Surgical consultation and imaging obtained



OR for debridement, abscess drainage, and cystoscopy. Ureteral perforation confirmed.



SICU stay with polymicrobial growth in blood and wound



Discharged home in 14 days with RP drain

## DISCUSSION

- Necrotizing fasciitis of the abdomen, thorax, and lower extremities has been described as a rare complication of emphysematous pyelonephritis.<sup>1,2,3,4</sup>
- Renal parenchymal and ureteral involvement necessitates prompt urologic evaluation in addition to general surgery intervention.
- Given the early recognition of renal involvement in our patient, infection source control was quickly and effectively obtained.

## CONCLUSION

- Identifying intra-abdominal sources of extremity infections facilitates rapid surgical source control.
- CT imaging can help guide surgical planning, disposition, and further elucidate infection sources.
- Patients with evidence of necrotizing infections should be promptly started on broad spectrum antibiotics and have an urgent surgical consultation.

## REFERENCES

1. Khaladkar SM, Jain KM, Kuber R, Gandage S. Necrotizing Fasciitis of Thoracic and Abdominal Wall with Emphysematous Pyelonephritis and Retroperitoneal Abscess. J Clin Imaging Sci. 2018;8:7.
2. El ammari JE, Ahssaini M, El fassi MJ, Farih MH. Retroperitoneal-necrotizing fasciitis due to chronic pyelonephritis. J Emerg Trauma Shock. 2010;3(4):419-20.
3. Ye YX, Wen YK. Emphysematous pyelonephritis presenting as necrotizing fasciitis of the leg. J Chin Med Assoc. 2009;72(3):160-2.
4. Kamel H, Awed MS, Kotb AF. Pyelonephritis can be a source of a life-threatening necrotizing myofasciitis. Can Urol Assoc J. 2014;8(5-6):E462-5.